

Notice: Because of current public health concern, this article is being published early (on November 8, 2001). It will appear in the November 29 issue of the *Journal*.

Brief Report

INDEX CASE OF FATAL INHALATIONAL ANTHRAX DUE TO BIOTERRORISM IN THE UNITED STATES

LARRY M. BUSH, M.D., BARRY H. ABRAMS, M.D., ANNE BEALL, B.S., M.T., AND CAROLINE C. JOHNSON, M.D.

SINCE the mid-1990s, *Bacillus anthracis*, the causative agent of anthrax, has been postulated to be a likely agent of biological warfare or terrorism because of its physical properties and its virulence factors. Several countries have been known to have biologic-weapons programs that were focusing on *B. anthracis* for potential military use. However, fatal anthrax had not been encountered in the United States as a weapon in an act of war or terror until the index case we report was recognized¹.

Anthrax is a rare bacterial infection acquired by inhalation, ingestion, or cutaneous contact with the endospores of *B. anthracis*.² The organism is normally a pathogen of large herbivorous mammals, and infection in humans normally results from contact with infected animals or contaminated animal products, especially hides. Inhalational anthrax is particularly rare and, in previous eras, has usually been fatal once the disease is established. Of the few cases reported in the United States, almost all have been associated with occupational exposure to endospores. We present the first case of inhalational anthrax to occur in the United States since 1978; it is an especially important case because of its origin in an act of biologic terrorism.

CASE REPORT

On October 2, 2001, a 63-year-old man was taken by his wife to the emergency department of a Florida medical center after he awoke from sleep with fever, emesis, and confusion. The patient had fever, myalgias, and malaise for the preceding four days but had not identified any localized symptoms. Specifically, he had not had a sore throat, rhinorrhea, or other upper respiratory tract symptoms. Because he was disoriented at the time of his presentation at the hospital, he was unable to provide further relevant information. Treatment with intravenous cefotaxime and vancomycin was initiated for presumed bacterial meningitis while the patient awaited lumbar puncture.

The patient had a history of mild hypertension and placement of a coronary stent for atherosclerotic heart disease. Otherwise,

he had been in good health. His only regular medications were daily metoprolol and aspirin.

The patient was a nonsmoker and an avid outdoorsman whose pastimes were gardening and fishing. Four days before he was admitted to the hospital, the patient had been in good health and had left for a brief recreational trip to North Carolina. Immediately on his arrival in North Carolina, the first symptoms of illness developed; these included muscle aches, nausea, and fever. The symptoms waxed and waned for the duration of the three-day trip. The day after he returned home, he was taken to the hospital for medical evaluation. During the trip, he had spent time outdoors, but he could identify no unusual exposure, including exposure to animals or animal hides. The patient was employed as a photo editor for a major tabloid newspaper and had been working until the day he departed for North Carolina. His duties usually kept him in a large office building in Florida, where he spent most of the day reviewing photographs submitted by mail or over the Internet.

On physical examination, he was found to be lethargic and disoriented. His temperature was 39°C (102.5°F), the blood pressure was 150/80 mm Hg, the pulse was 110, and the respirations were 18. No respiratory distress was noted; his arterial hemoglobin saturation, as indicated by pulse oximetry while he was breathing ambient air, was 97 percent. No evidence of trauma was noted on examination of the head. Funduscopic examination was normal, as were the conjunctiva. Examination of the ear, nose, and throat detected no discharge or signs of inflammation. There was no discernible nuchal rigidity; Kernig's and Brudzinski's signs were absent. The trachea was at midline, and there was no edema of the cervical or thoracic region. Chest examination revealed bibasilar rhonchi without rales. No murmurs, rubs, or gallops were heard on cardiac auscultation. The abdomen was soft, without rebound tenderness or organomegaly. Examination of the joints, legs, and arms was essentially normal. No lesions or rashes were noted on the skin. No focal deficits were noted on neurologic examination; there were no cranial-nerve palsies.

The results of the patient's laboratory tests on hospital admission are shown in Table 1. The initial chest radiograph (Fig. 1) was interpreted as showing basilar infiltrates and a widened mediastinum. The results of computed tomography of the head, performed without intravenous contrast medium, were normal. A spinal tap was performed under fluoroscopic guidance within hours after presentation at the hospital and yielded cloudy cerebrospinal fluid (Table 1). Gram's staining of cerebrospinal fluid revealed many polymorphonuclear white cells and many large gram-positive bacilli, both singly and in chains (Fig. 2).

On the basis of the cerebrospinal fluid appearance, a diagnosis of anthrax was considered, and high-dose intravenous penicillin G was added to the antibiotic regimen. Within six hours after plating on sheep's-blood agar, the cultures of cerebrospinal fluid yielded colonies of gram-positive bacilli (Fig. 3). The clinical laboratory of the medical center presumptively identified the organism as *B. anthracis* within 18 hours after plating; this identification was confirmed by the Florida Department of Health laboratory on the following day (Table 2).⁴ Multiple blood cultures obtained on admission were also ultimately positive for *B. anthracis*.

Within hours after admission, the patient had a generalized grand mal seizure and was intubated to protect his airway and so that ventilatory assistance could be provided. After intubation, the arterial blood gas values while the patient was receiving supplemental oxygen (fraction of inspired oxygen, 50 percent) were as follows: a pH of 7.31, a partial pressure of carbon dioxide of 37 mm Hg, and a partial pressure of oxygen of 208 mm Hg. On the second hospital day, hypotension and azotemia developed; although there was initially a response to vasopressor treatment, oliguric renal failure with hyperkalemia and acidosis ensued. Continuous arterial-venous hemoperfusion was begun. The patient remained consistently febrile (maximal temperature, 40°C [104°F]) and tachycardic, and he never regained consciousness during the remaining course of hospitalization. On the third hospital day, despite aggressive medical treatment, refractory hypotension developed, and the patient had an asystolic cardiac arrest and died despite attempts at resuscitation.

From Infectious Disease Associates, Atlantis Medical Center, Atlantis (L.M.B., B.H.A.), and Integrated Regional Laboratories, Ft. Lauderdale, (A.B.) — both in Florida; and the Division of Disease Control, Philadelphia Department of Public Health, Philadelphia (C.C.J.) Address reprint requests to Dr. Bush at 5503 S. Congress Ave., Suite 102, Atlantis, FL 33462.

TABLE 1. INITIAL LABORATORY FINDINGS.*

VARIABLE	VALUE
Hematologic	
Hemoglobin (g/dl)	16.1
Hematocrit (%)	46
White-cell count (per mm ³)	9,400
Differential count (%)	
Polymorphonuclear cells	77
Lymphocytes	15
Monocytes	8
Platelet count (per mm ³)	109,000
Serum chemical	
Glucose (mg/dl)	174
Creatinine (mg/dl)	1.1
Urea nitrogen (mg/dl)	20
Sodium (mmol/liter)	132
Potassium (mmol/liter)	3.9
Chloride (mmol/liter)	97
Bicarbonate (mmol/liter)	23
Calcium (mg/dl)	8.7
Albumin (g/dl)	4.0
Total protein (g/dl)	7.3
Total bilirubin (mg/dl)	1.5
Alkaline phosphatase (U/liter)	61
Aspartate aminotransferase (U/liter)	30
Cerebrospinal fluid	
Appearance of fluid	Cloudy
Glucose (mg/dl)	57
Protein (mg/dl)	666
Red-cell count (per mm ³)	1,375
White-cell count (per mm ³)	4,750
Differential count (%)	
Polymorphonuclear cells	81
Monocytes	19

*To convert the values for glucose to millimoles per liter, multiply by 0.05551. To convert the value for creatinine to micromoles per liter, multiply by 88.4. To convert the value for urea nitrogen to millimoles per liter, multiply by 0.357. To convert the value for calcium to millimoles per liter, multiply by 0.250. To convert the value for bilirubin to micromoles per liter, multiply by 17.1.

There was no disseminated intravascular coagulation during the brief hospitalization, nor did cardiac arrhythmias or the acute respiratory distress syndrome occur.

An autopsy was performed (under the auspices of the Medical Examiner's office) and revealed generalized tissue edema with extensive collections of fluid from the peritoneal cavity. Partial collapse of the lungs was noted, with areas of subpleural and perivascular hemorrhage. No pulmonary parenchymal consolidation was detected. In the mediastinum, there was an accumulation of 50 ml of gross blood. Several enlarged lymph nodes (1 to 2 cm) were also noted; on cross-sectional examination, the lymph nodes were hemorrhagic, but organisms were not detected on Gram's staining. There were no gross abnormalities of the heart, liver, or spleen. No examination of the central nervous system was performed (Flannagan L, District Medical Examiner, Palm Beach County, Fla.: personal communication).

DISCUSSION

The finding of hemorrhagic spinal fluid with gram-positive bacilli yielded the earliest clue to the diagnosis of anthrax in this patient. The organism's appearance was not suggestive of listeria, which typically appears small and slender on staining. Although the appearance of the organism was certainly consistent

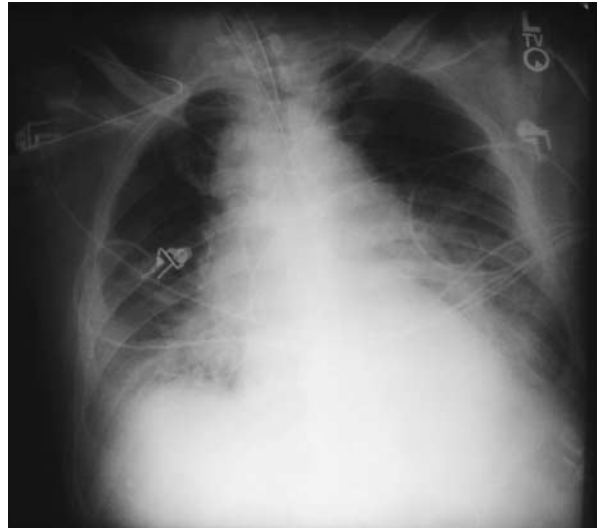


Figure 1. Anteroposterior Chest Radiograph Obtained on Admission, Showing the Widened Mediastinum That Is Characteristic of Anthrax.

A chest radiograph obtained approximately one year before the fatal illness showed a normal mediastinal shadow.

with another bacillus species, such as *B. cereus* or *B. subtilis*, these pathogens would not have been expected to be found in an otherwise healthy man. It was evident that making a diagnosis of anthrax would have serious ramifications. Although the case was reported to local public health authorities when anthrax was first suspected, final laboratory confirmation of the diagnosis was awaited before a public announcement was made.

The clinical manifestations of inhalational anthrax in this case were typical. Several days of a nonspecific prodrome of fever, malaise, and myalgia were followed by a fulminant course characterized by seizures and subsequent respiratory failure, although pneumonia was notably absent, both clinically and at autopsy. Hemorrhagic mediastinitis, initially suggested by a widened silhouette on chest radiography and confirmed at autopsy, may have contributed to the respiratory failure. The time from the onset of symptoms to death was six days — a period similar to the median interval of three days reported in a recent review.² Meningitis, a complication reported in less than 5 percent of cases of anthrax, accompanied septicemia in this case.

Inhalational anthrax develops after the deposition of pathogenic endospores of *B. anthracis* into the alveolar spaces. There, endospores are engulfed by macrophages, are transported to mediastinal and peribronchial lymph nodes, and then germinate, becoming a vegetative form that causes toxemia and massive septicemia. When dispersed in the air as 1-to-5- μ m par-

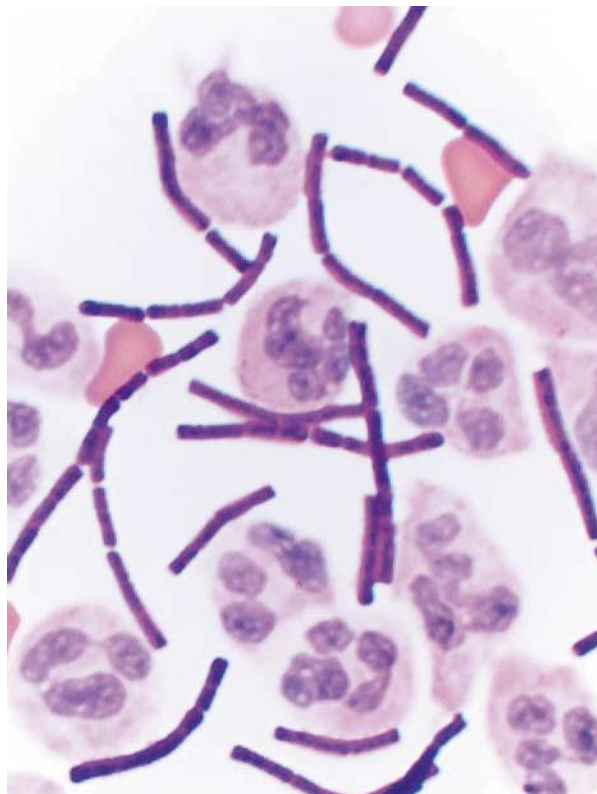


Figure 2. Cerebrospinal Fluid Specimen Containing Many Polymorphonuclear White Cells and Gram-Positive Bacilli (Gram's Stain, $\times 1000$).

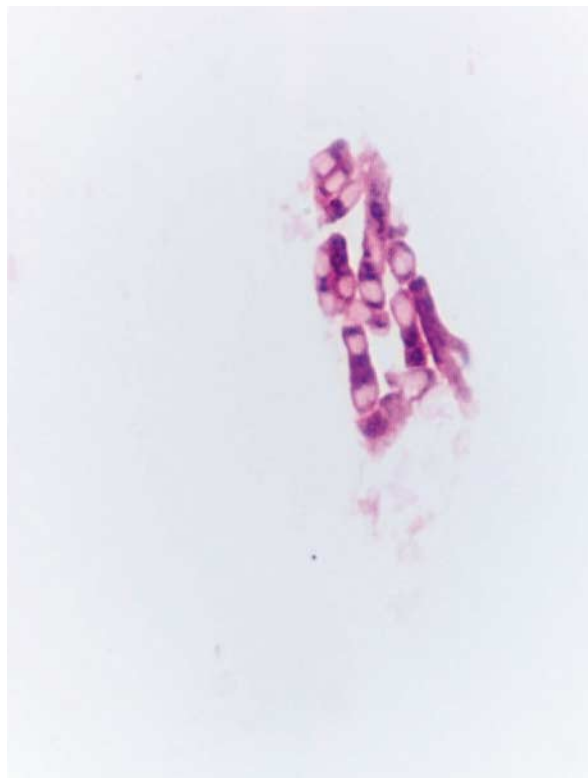


Figure 3. Colonial Growth of *Bacillus anthracis* on Sheep's-Blood Agar, with Subterminal and Central Spores (Gram's Stain, $\times 1000$).

ticles, *B. anthracis* endospores may pose a risk even over large geographic distances. After an accidental release of endospores from a military biologic-weapons facility in Sverdlovsk, Russia, cases of anthrax in humans occurred as far as 4 km from the site, and cases in animals occurred as far as 50 km away.^{5,6}

Since the beginning of the 20th century, most cases of inhalational anthrax in the United States have resulted from occupational exposure to contaminated animal hides. On the basis of data from experiments in primates, the dose of inhaled anthrax that is likely to be lethal in half of the humans infected is between 2500 and 55,000 endospores. But even among workers in mills where goat hair is processed, who are exposed regularly to high concentrations of endospores,⁶ few clinical cases have been observed. Studies suggest that there is wide variation in individual susceptibility to anthrax infection.

Oddly, the present case was also caused by occupational exposure to anthrax, although not by a naturally occurring means. The presence of anthrax endospores in the patient's work environment (e.g., in the computer keyboard), as well as in asymptomatic

TABLE 2. LABORATORY FINDINGS LEADING TO THE IDENTIFICATION OF *BACILLUS ANTHRACIS*.*

Clinical-laboratory findings (level A)

Large, broad gram-positive bacillus
Rapid, aerobic growth
Central and subterminal spores
Nonhemolytic on sheep's-blood agar
Nonmotile
Sensitive to penicillin (40-mm zone with 10-unit disk)

Reference-laboratory findings (level B)

Lysis by gamma phage
Capsular-specific staining
Polysaccharide-cell-wall antigen staining

*Identification of *B. anthracis* was performed according to the protocols of the Laboratory Response Network for Bioterrorism, a network of laboratories established by the Centers for Disease Control and Prevention and the Association of Public Health Laboratories to identify agents of bioterrorism safely and rapidly.³ The medical center's clinical laboratory performed the level A tests. The Florida Department of Health laboratory performed the confirmatory level B tests.

coworkers, confirmed the building as the site where the infection had been acquired.⁷ Extensive environmental samples from the patient's home and travel destinations were negative for anthrax. Moreover, the finding of *B. anthracis* in regional and local postal centers that served the work site implicates one or more mailed letters or packages as the probable source of exposure. Coworkers report that the patient had closely examined a suspicious letter containing powder on September 19, approximately eight days before the onset of illness. (This incubation period is highly plausible, given the modal incubation period of 10 days reported in the Sverdlovsk outbreak.⁵) Since this case was recognized, other cases of inhalational and cutaneous anthrax have been reported in several different states. To date, nearly all these cases have occurred in persons with confirmed or suspected contact with contaminated mail or in persons at high risk for such contact (i.e., postal workers).³ Epidemiologic and criminal investigation of this biologic-terrorism-related outbreak of anthrax is ongoing. This index case highlights the importance of physicians' ability to recognize potential cases in the identification and treatment of diseases associated with biologic terrorism.

Because of the media attention that surrounded the occurrence of this case, we realize that the patient's anonymity cannot be ensured. We are grateful to the patient's wife, who permitted the presentation of this case in order to advance medical knowledge. We are also indebted to Sharon Reuben for technical assistance in the preparation of the manuscript.

REFERENCES

1. Inglesby TV, Henderson DA, Bartlett JG, et al. Anthrax as a biological weapon: medical and public health management. *JAMA* 1999;281:1735-45.
2. Dixon TC, Meselson M, Guillemin J, Hanna PC. Anthrax. *N Engl J Med* 1999;341:815-26.
3. Malecki J, Wiersma S, Cahill H, et al. Update: investigation of bioterrorism-related anthrax and interim guidelines for exposure management and antimicrobial therapy, October 2001. *MMWR Morb Mortal Wkly Rep* 2001;50(42):909-19.
4. Biological and chemical terrorism: strategic plan for preparedness and response. *MMWR Morb Mortal Wkly Rep* 2000;49(RR-4).
5. Meselson M, Guillemin J, Hughes-Jones, M et al. The Sverdlovsk anthrax outbreak of 1979. *Science* 1994;266:1202-8.
6. Swartz MN. Recognition and management of anthrax — an update. *N Engl J Med* 2001;345:1621-6.
7. Bush L, Malecki J, Wiersma S, et al. Update: investigation of anthrax associated with intentional exposure and interim public health guidelines, October 2001. *MMWR Morb Mortal Wkly Rep* 2001;50(41):889-93.

Copyright © 2001 Massachusetts Medical Society.